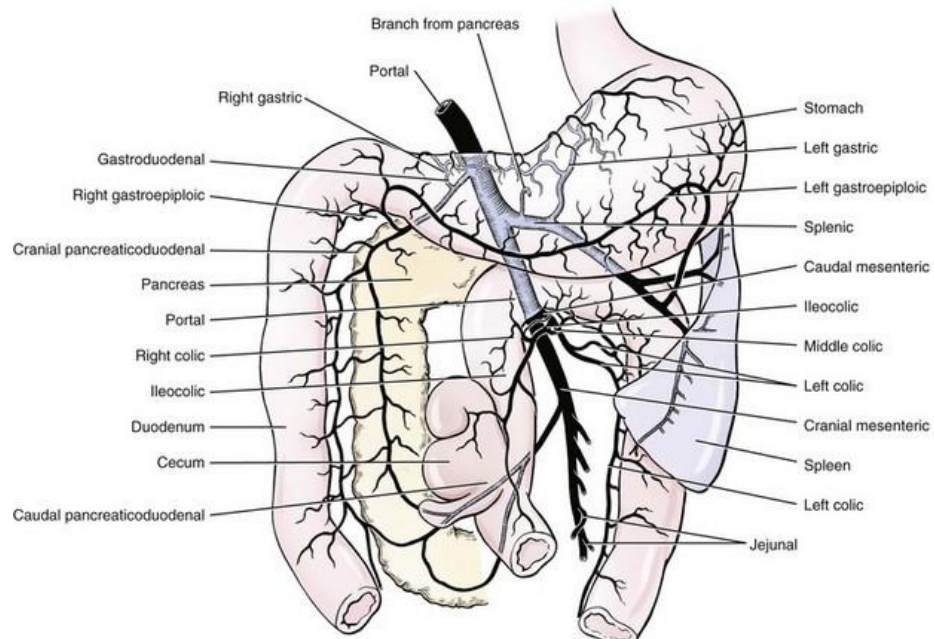


## PORTOSYSTEMIC SHUNTS (portosystemic vascular anomalies)

The blood draining from the stomach, intestines, pancreas and spleen (portal blood) has to pass through the liver before going into the systemic circulation. Portosystemic shunts are abnormal vessels through which the portal blood bypasses the liver and enter the systemic circulation. Usually purebred dogs are at an increased risk of harboring portosystemic shunts.



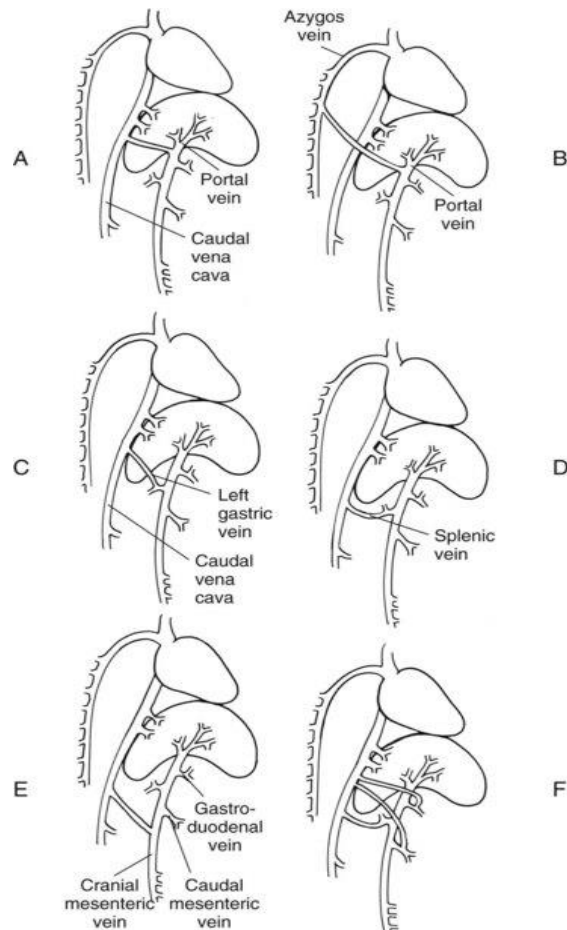
Tributaries of the portal vein in a dog: ventral aspect. (From Evans HE, de Lahunta A: Miller's anatomy of the dog, ed 4, St Louis, 2013, Saunders/Elsevier.)

There are two main types of shunts, *extrahepatic* – shunts located outside the liver parenchyma and *intrahepatic* – shunts located inside the liver parenchyma

A *portocaval shunt* is a shunt from portal vein to caudal vena cava.

Types of portosystemic shunts in dogs and cats.

A, Portal vein to caudal vena cava. B, Portal vein to azygos vein. C, Left gastric vein to caudal vena cava. D, Splenic vein to caudal vena cava. E, Left gastric, cranial mesenteric, caudal mesenteric, or gastroduodenal vein to caudal vena cava. F, Combinations of the above. (From Fossum TW, editor: Small animal surgery, ed 3, St Louis, 2007, Mosby/Elsevier.)



**Diagnosis** is based on the signalment, history (failure to grow, small body stature or loss of body weight and varied signs), from physical examination findings (like microhepatica, prominent kidneys, neurological abnormalities). A confirmatory diagnosis may be achieved with contrast radiography, ultrasonography and nuclear imaging.

**Treatment:** Surgical correction which aims at attenuation of the shunts.

## NEOPLASIA

Primary and Metastatic tumours have been encountered in animals. **Primary tumours** are less common compared to metastatic tumours, e.g. hepatocellular carcinomas may develop as solitary mass or in diffuse multiple nodules; bile duct carcinomas; hepatomas etc. **Metastatic tumours** are more common than primary tumours, e.g. originating from the spleen (haemangiosarcoma); originating from the colon (adenocarcinoma); originating from the pancreas (adenocarcinoma, islet cell carcinoma); originating from the lymph nodes (Lymphosarcoma).

Clinical signs are weight loss, cachexia, jaundice, ascites, anaemia, vomiting and diarrhoea.

*Treatment:* Radical surgery involves excision of the mass by either wedge resection or finger fracture technique. Large masses can also be treated by total or subtotal lobectomy

## HEPATIC ABSCESS

These are rare in dogs and cats but may be the result of infection. They may develop due to haematogenous spread of infectious agents, penetrating foreign objects, extension of biliary infections, or localized peritonitis (necrotizing pancreatitis)

*Symptoms* are prolonged and undulant fever (Suspect hepatic abscessation in case of pyrexia of unknown origin), anorexia, abdominal pain and vomiting

*Diagnosis-* Serum biochemistry, Ultrasonography and Radiography

*Treatment:* Surgical drainage (Preferable for solitary abscess) and/or Antimicrobial therapy

## TRAUMA of liver

It may result from automobile accidents, gunshot wounds, falling from heights and rupture of necrotic tumours and can be classified as- trans-capsular, sub-capsular and central.

*Symptoms:* Hypovolaemia due to Acute blood loss, endotoxaemia (coliform or anaerobic), bile peritonitis

*Diagnosis:* is based on haematology and serum biochemistry, radiography and ultrasonography and from peritoneal lavage and centesis

*Treatment* – Should include management of shock, control of haemorrhage and the surgery should aim at excision of dead liver tissue, suturing the lacerated liver tissue, control of haemorrhage, and drainage of bile contents from the peritoneal cavity

## CHOLELITHIASIS

Also known as gall stones and is rare in dogs. It causes obstruction to the flow of bile. The stones are formed by the precipitation of supersaturated cholesterol or bilirubin in the bile. Obstruction to the flow of bile leads to subsequent clinical signs which include abdominal pain, vomiting, steatorrhoea and jaundice.

*Diagnosis:* is based on contrast radiography (Intravenous or oral cholecystography) – because majority of the gall stones may be radiolucent, and ultrasonography.

*Treatment:* Incision of common bile duct and removal of the gall stones, Cholecystotomy

## SPLENECTOMY

It is the surgical removal of spleen. *Partial Splenectomy* is the removal of a part of spleen whereas *total Splenectomy* is the removal of whole spleen.

**Indications:** Partial splenectomy may be indicated in cases of traumatic lesions, splenic infarcts, focal lesions, while total Splenectomy may be indicated in cases of splenic neoplasia, splenic torsion, severe trauma, unsuccessful therapy for immune mediated haematological disorder. An elective Splenectomy is often performed in dogs used as donors to reduce the risk to transfer blood protozoa to uninfected animal during transfusion.

**Contraindication:** Patients with bone marrow hypoplasia where spleen is main site of haemopoiesis

**Consideration for splenectomy:** Special consideration should be directed towards the middle-aged or older patients, proper nutritional & metabolic status of patients and concurrent haematological disorders.

#### *Pathophysiology of disorders in which splenectomy is indicated*

In torsions splenic veins get occluded resulting congestive splenomegaly and vascular thrombosis, as in GDV. In some dogs clinical signs are acute. Splenic infarcts may be associated to liver or renal diseases, neoplasia or thrombosis associated in cardiovascular disease. There is sign of altered blood flow & coagulation. It may lead to haemoabdomen or sepsis. Anaemia may occur due to severe haemorrhage & may associate with disseminated intravascular coagulations. Malignant cancers may metastasize to other normal tissue while benign or nodular tissues are vulnerable to rupture & severe blood loss & shock.

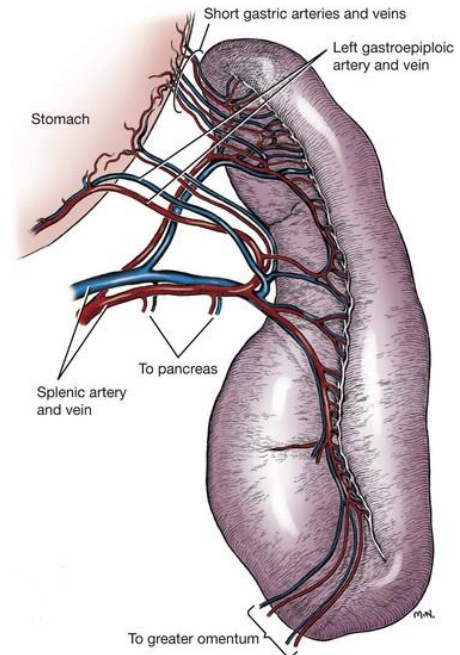
**Anatomical considerations:** Spleen is located in the left cranial abdominal quadrant. It usually lies parallel to the greater curvature of stomach but exact location depends on its size and position of other abdominal organs. In contracted stomach it lies in rib cage while in gastric enlargement it lies in caudal abdomen. It is covered by a capsule. It is attached to the stomach by gastrosplenic ligament. Blood supply is from splenic artery, a branch of celiac artery. The splenic artery gives off 3-5 primary branches in greater omentum towards ventral spleen. The venous drainage is via splenic vein into gastro splenic vein that empties into portal vein.

**Clinical presentation:** Splenic torsions and tumors occur in large breed dogs; age and sex no bar. Clinical signs presented are vomiting, anorexia, weakness & depression, icterus, hematuria or haemoglobinuria and abdominal pain. Acute torsion may result to shock.

**Physical examination:** splenic enlargement on palpation, abdominal distension in splenic rupture, abdominal pain, dehydration, pale mucus membrane or Icterus, tachycardia, longer capillary refilling time, weak peripheral pulse.

**Diagnosis:** is based on clinical signs, Radiography (splenic outline blurred, enlargement, radiopaque mass, etc.) and ultrasonography. Laboratory analysis reveals anaemia, leukocytosis, haemoglobinuria, increased serum alkaline phosphatase etc.

**Pre-operative medical management:** Fluid and electrolyte deficits should be corrected. Whole blood transfusion in severe blood loss is needed. Perioperative antibiotic therapy can be given. Cardiac status should be monitored.

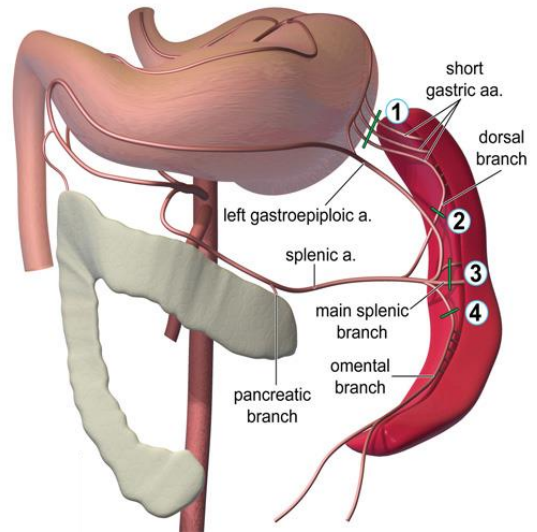


**Anaesthesia:** Oxygen is to be given before, during and after anaesthesia. Anticholinergics can be given for bradycardia. Barbiturates should be avoided as they cause splenic congestion. Similarly, acepromazine should be avoided as it causes hypotension. Propofol can be given safely.

**Site:** Paramedian in xiphoid area. Area to be prepared for aseptic surgery.

### Technique

**Partial splenectomy:** Laparotomy is performed in dorsal recumbency and the spleen is exposed. The desired area is to be defined and the hilar vessels supplying the area are double ligated and incised. Squeeze splenic tissue between thumb and forefinger at the line of lesion and milk splenic pulp towards lesion. Place forceps on either side of the line dividing healthy spleen and lesion and resect off the spleen between the forceps. Close cut surface in continuous pattern by absorbable suture. Double row can be applied. One or two rows of continuous overlapping mattress sutures can be applied. Haemorrhage can be controlled by surgical diathermy. The abdomen & skin can be closed in routine manner.



1, 2, 3 and 4- preferable sites of ligation of vessels

**Total splenectomy technique:** Laparotomy is performed in dorsal recumbency and the spleen is exposed. Place moistened abdominal sponges under spleen. Squeeze splenic tissue between thumb and forefinger. A small dose of adrenalin injected into the splenic tissue shrinks the spleen considerably. Double ligate and transect all the vessels at splenic hilus with absorbable or non-absorbable suture. Transect the attachment to stomach and remove spleen. Abdomen and skin can be closed as usual.

**Post-operative care:** Antibiotic and anti-inflammatory medication is to be done parenterally. Splenectomy requires a 24 hr monitoring for haemorrhage and fluid therapy to stabilize hypotension. Surgical site should be dressed daily. Long term antibiotic therapy is required to counteract the immunosuppression. Skin suture can be removed after 10-14 days.

**Complications:** Haemorrhage, Immunosuppression.